

■ Brief Report

# Innoxious Removal of Suction Drains

CHRISTOS K. YIANNAKOPOULOS, MD\*†; ANASTASSIOS D. KANELLOPOULOS, MD†

## abstract

Suction drains are commonly used in orthopedic elective and trauma surgery; however, drain tube removal causes pain, discomfort, and anxiety. A method of drain tube removal is described in patients who underwent total hip replacement and in adolescents who underwent lower extremity surgery. Ten milliliters of lidocaine was injected through the skin wound around the drain tube. The efficiency of this practice was evaluated using a visual analog scale score in two patient groups. Pain during tube removal and pain on post-removal were significantly decreased in the study group compared to the placebo group. Using this technique drain tube removal was painless, comfortable, and safe.

Closed suction drainage systems are used frequently in orthopedic and trauma surgery to drain blood from the surgical operation site. The primary function of these devices is to prevent hematoma formation, wound dehiscence, and infection. Several studies support or reject suction drainage in orthopedic surgery; however, the final decision relies on the surgeon's preference.<sup>1-6</sup> Frequently performed by non-physicians, drain removal is an unpleasant procedure that causes pain and anxiety.<sup>7,8</sup>

*From the \*Orthopedic Department, Veterans Army Hospital, and the †Pediatric Orthopedic Department, KAT Accident Hospital, Athens, Greece.*

*The authors thank Dr E. Michelinakis and Dr Th. Papapolychroniou for their continuous support and encouragement.*

*Reprint requests: Christos K. Yiannakopoulos, MD, Byzantiou 2, 171 21 Nea Smyrni, Athens, Greece.*

Practices associated with drain removal vary considerably. The effect of fast versus slow drain removal and the efficiency of pre-removal administered analgesic drugs have not been reported in the orthopedic literature. The administration of morphine, midazolam, EMLA (AstraZeneca, Wilmington, Del), isoflurane, nitrous oxide, and lidocaine has been advocated to provide anesthesia during thoracostomy tube removal; however, no technique has attained complete pain eradication.<sup>9-11</sup>

This article describes patient reaction to drain removal and validates a method to reduce pain and anxiety caused by drain removal.

## MATERIALS AND METHODS

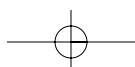
This study comprised 102 patients who were enrolled between 2000 and 2001 and was approved by the Institutional Ethics Committee. All patients had undergone

hybrid total hip replacement for primary osteoarthritis using the posterolateral approach. After the operation, a #16 French closed suction drain tube was placed in the surgical wound close to the replaced acetabulum penetrating the fascia lata and the skin exiting at the lower part of the wound, posteriorly to the surgical incision. The distance between the drain and the skin wound was approximately 4 cm. The drain was removed 48 hours post-operatively.

Sensations following drain removal were recorded for the first 20 patients, whereas in the remaining 82 patients, the efficiency of a pain-minimizing technique was examined. The remaining 82 patients were randomly allocated into two groups, A and B, with 41 patients in each group.

In group A, 10 mL of lidocaine 1% (AstraZeneca) was instilled into the skin wound around the drain; in group B, no anesthetic measure was undertaken. During the instillation, the local anesthetic was dispersed around the plastic tube to anesthetize the skin and subcutaneous tissue. No effort was made to inject the deepest wound tissues. The procedure was comfortable and no pain or discomfort was reported compared to the pain perceived by patients during subcutaneous lidocaine administration.

Pain intensity was assessed based on a



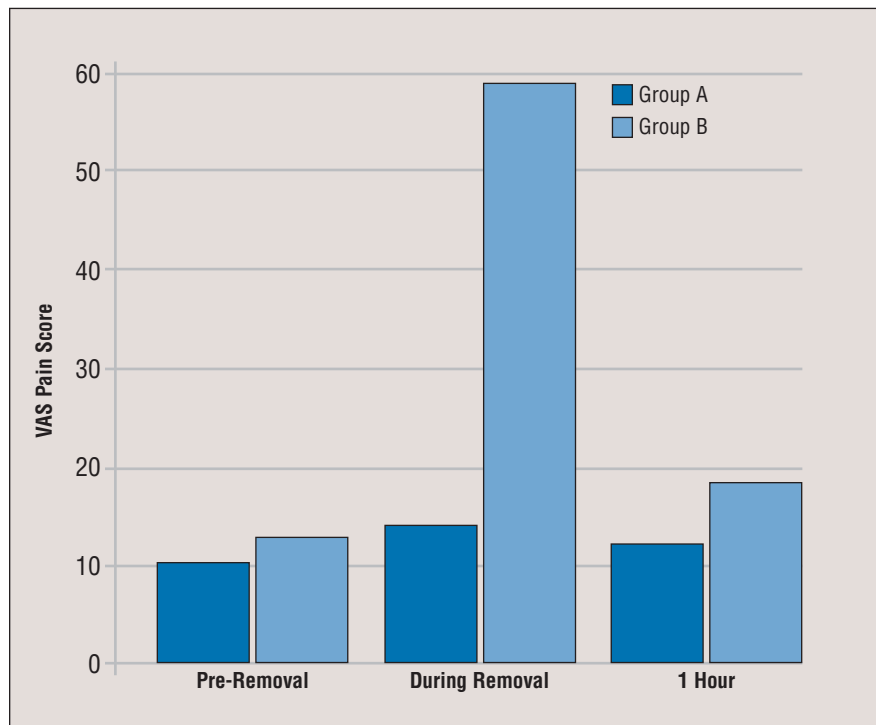
vertical 100-mm visual analog scale (VAS) score from 0 (no pain) to 100 (worst possible pain) on three occasions: before drain removal, during removal, and one hour post-removal. The difference between the pain scores between the two groups was statistically evaluated using the unpaired *t* test and the level of significance was  $P=.05$ .

A group of 18 adolescents who underwent lower extremity surgery also were included in the study to examine the effectiveness of the removal method in this age group. Mean patient age was  $13\pm 3$  years. Each patient had one drain inserted into the surgical wound. Operations performed were femoral fracture nailing ( $n=13$ ), bone grafting ( $n=3$ ), and biopsy ( $n=2$ ). Five milliliters of lidocaine was instilled into the skin wound around the drain tube and the pain response on drain removal was evaluated using the same VAS score. We believed exposing the adolescents to pain would be unethical and thus no control group was included.

## RESULTS

In the first 20 patients, the drains were removed without anesthesia. Most patients experienced sharp and burning pain following drain removal, which lasted  $<5$  minutes and was followed by persistent soreness for approximately 1 hour. Pain sensation was usually maximal when the final, non-smooth, perforated part of the drain emerged through the skin. In the first cases, the drain was removed swiftly, but the procedure was more painful and was abandoned. In all remaining cases, the drain was slowly removed during a 15-second period. The mean VAS pain score prior to drain removal was  $13\pm 5$ , during removal  $69\pm 21$ , and 1 hour after removal  $24\pm 06$ .

Mean patient age in groups A and B was  $67\pm 7.2$  years (range: 56-79 years). No difference was noted in terms of sex, mean age, and quantity of fluid discharge between the two groups. Three VAS scores were used before, during, and after removal. The difference between the first



**Figure:** Visual analog pain intensity scores on a scale of 0 to 100 in groups A (lidocaine infiltration) and B (no infiltration). Abbreviation: VAS=visual analog scale.

and the other two measurements as well as between the second and the third measurement was statistically significant ( $P<.001$ ). In group B where no wound infiltration was undertaken, the mean pain VAS scores pre-removal, during removal, and 1 hour after removal were  $13\pm 4$ ,  $59\pm 11$ , and  $28\pm 9$ , respectively. In group A where the drain wound was infiltrated with lidocaine, the VAS scores were  $11\pm 2$ ,  $14\pm 4$ , and  $12\pm 5$ , respectively (Figure 1). The differences between the pain scores were statistically different during drain removal and 1 hour after

removal ( $P<.05$ ). No skin infections occurred, and all wounds healed without complications.

In the adolescent group, the pain scores pre-removal, on removal, and 1 hour after removal were  $18\pm 6$ ,  $14\pm 7$ , and  $15\pm 5$ , respectively. No significant difference was noted between the three scores.

## DISCUSSION

In a cohort of elderly and adolescent patients it was determined that local instillation of lidocaine around the drain tube significantly reduces pain on drain

### What is already known on this topic

- Painless suction drain removal has not been specifically addressed in the orthopedic literature, despite the profound discomfort this procedure causes the patient.

### What this article adds

- This article presents a technique that reduces or eliminates drain removal pain, thus increasing patient comfort.



## Brief Report

removal, increasing patient comfort during the post-removal period.

Drains are inserted to evacuate established or drain potential fluid collections; however, their use in total joint replacement is controversial.<sup>1-6</sup> Several studies support their use,<sup>2-5</sup> whereas others reject it as being unnecessary, especially in the hip.<sup>1,6,12</sup> The final decision regarding drain use relies on the surgeon's preferences.

Drain removal, usually 24 or 48 post-operatively,<sup>5,6,13</sup> a sometimes painful and frustrating experience, has attracted little attention in the orthopedic literature. Cutaneous and subcutaneous nociceptors contribute to drain tube removal pain. In our study, most patients described sharp and burning pain; patients with rapid drain removal experienced more pain compared to those with slow removal. Pain was experienced especially when the final, non-smooth part of the tube passed through the skin wound; no patient reported deep wound pain. The anesthetization of the skin with lidocaine offered almost complete anesthesia during tube removal as well as during the first hour after removal, increasing patient comfort.

The pain experienced was measured using a VAS. Visual analog scales are used in the social and behavioral sciences to measure a variety of subjective phenomena, providing a simple, efficient, non-invasive measurement of pain intensity. In our study, VAS pain intensity scores between groups A and B differed during drain removal and the first post-removal hour but not prior to removal.

Several studies have examined the sensations experienced during thoracostomy tube removal, and measures to prevent pain have been proposed and undertaken. Patients with a mediastinal or a pleural tube experience burning pain during drain removal. Two tablets of acetaminophen-

oxycodone administered within 2 hours prior to chest tube removal has no effect on the pain sensation.<sup>7</sup> Several anesthetic agents have been administered prior to chest drain removal. Nitrous oxide 50% in oxygen with or without isoflurane 0.25% is effective in reducing removal pain.<sup>9</sup> Morphine 2 mg and midazolam 2 mg given intravenously 5 minutes before or intravenous propofol 0.7-1 mg·kg<sup>-1</sup> 1 minute before chest tube removal are effective in alleviating removal pain.<sup>10</sup> The doses of morphine used vary considerably among different centers.<sup>8</sup>

The use of suction drain tubes as catheters to inject local anesthetics into the surgical wound to provide anesthesia has been proposed.<sup>14</sup> In joint replacement patients, this technique may cause retrograde bacterial seeding and should be avoided. Five milligrams of EMLA cream, an eutectic mixture of lidocaine and prilocaine, applied transdermally 3 hours before thoracostomy tube removal was compared to intravenous morphine 0.1 mg·kg<sup>-1</sup>.<sup>11</sup> The cream was more effective than intravenous morphine in preventing chest tube pain and it effectively reduces thoracostomy tube removal pain providing analgesia in pediatric patients.<sup>15</sup> Thoracostomy tubes are larger (#36 to #40 French in adults) compared to the drains used in joint replacement (#12 to #16 French). Additionally, thoracostomy tube insertion is more traumatic and the procedure is performed in an area more sensitive to nociceptive stimuli (ie, the upper part of the chest in the third to fifth intercostal space). ■

## REFERENCES

- Acus RW III, Clark JM, Gradisar IA Jr, Kovacic MW. The use of postoperative suction drainage in total hip arthroplasty. *Orthopedics*. 1992; 15:1325-1328.
- Berman AT, Fabiano D, Bosacco SJ, Weiss

AA. Comparison between intermittent (spring-loaded) and continuous closed suction drainage of orthopedic wounds: a controlled clinical trial. *Orthopedics*. 1990; 13:309-314.

- Holt BT, Parks NL, Engh GA, Lawrence JM. Comparison of closed-suction drainage and no drainage after primary total knee arthroplasty. *Orthopedics*. 1997; 20:1121-1125.
- Kim YH, Cho SH, Kim RS. Drainage versus nondrainage in simultaneous bilateral total hip arthroplasties. *J Arthroplasty*. 1998; 13:156-161.
- Kim YH, Cho SH, Kim RS. Drainage versus nondrainage in simultaneous bilateral total knee arthroplasties. *Clin Orthop*. 1998; 347:188-193.
- Niskanen RO, Korkala OL, Haapala J, Kuokkanen HO, Kaukonen JP, Salo SA. Drainage is of no use in primary uncomplicated cemented hip and knee arthroplasty for osteoarthritis: a prospective randomized study. *J Arthroplasty*. 2000; 15:567-569.
- Gift AG, Bolgiano CS, Cunningham J. Sensations during chest tube removal. *Heart Lung*. 1991; 20:131-137.
- Kinney MR, Kirchhoff KT, Puntillo KA. Chest tube removal practices in critical care units in the United States. *Am J Crit Care*. 1995; 4:419-424.
- Bryden FM, McFarlane H, Tunstall ME, Ross JA. Isoflurane for removal of chest drains after cardiac surgery. *Anaesthesia*. 1997; 52:173-175.
- McMurray TJ, Bhanumurthy S, Groogan F. Low dose propofol for chest tube removal. *Anaesthesia*. 1995; 50:566.
- Valenzuela RC, Rosen DA. Topical lidocaine-prilocaine cream (EMLA) for thoracostomy tube removal. *Anesth Analg*. 1999; 88:1107-1108.
- Ovadia D, Luger E, Bickels J, Menachem A, Dekel S. Efficacy of closed wound drainage after total joint arthroplasty. A prospective randomized study. *J Arthroplasty*. 1997; 12:317-321.
- Drinkwater CJ, Neil MJ. Optimal timing of wound drain removal following total joint arthroplasty. *J Arthroplasty*. 1995; 10:185-189.
- Pelissier P. Painless postoperative period and drain removal using local anesthesia. *Plast Reconstr Surg*. 2003; 111:514-515.
- Rosen D, Morris J, Rosen K, et al. Analgesia for pediatric thoracostomy tube removal. *Anesth Analg*. 2000; 90:1025-1028.

